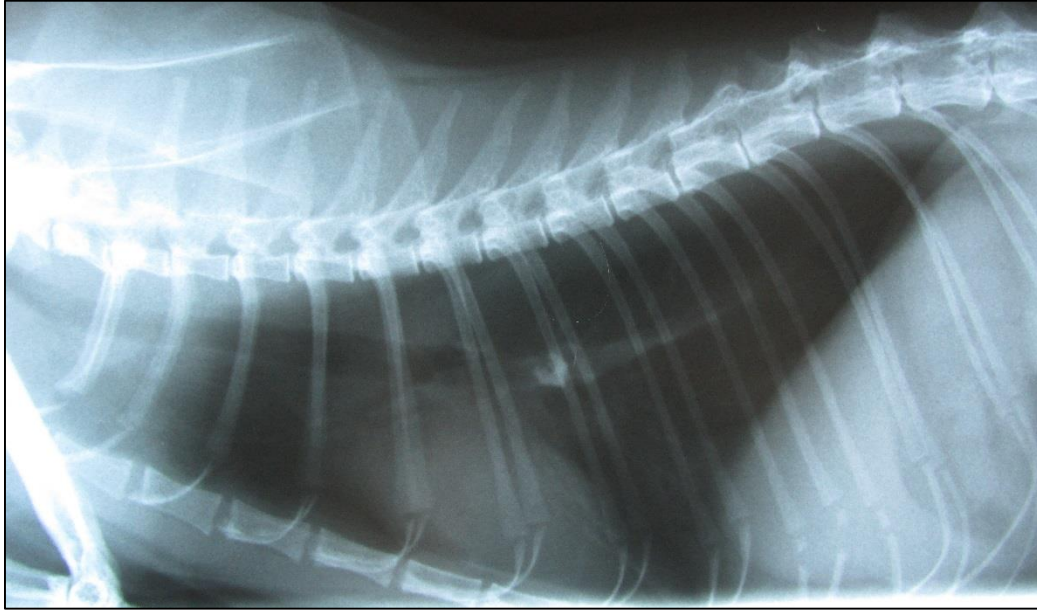


## Gabby and the missing tooth



Gabby is a very handsome grey 7 year old female domestic short haired cat. Her owners took her to their vet when she suddenly started coughing violently one weekend. The cough would end with a retch but she never brought up food and was eating well. She was less active than normal and looked a bit out of sorts. Her vets took an x-ray (spot the tooth above).

Gabby's vet referred her to King Edward Referrals. A quick check showed that Gabby was missing her left lower premolar no 2. We gave her a short anaesthetic and removed the tooth with an endoscope. We were able to pull it back out through the windpipe so Gabby didn't need surgery.

The photos illustrate this: Top right is what we saw when we used the endoscope (flexible camera thing like the one right) to look down Gabby's windpipe. We used a basket (almost bottom right) that we passed through the endoscopy to capture the tooth and pull it out of her airways. Bottom right is the misplaced tooth. Not sure what the tooth fairy paid for that one. Gabby tucked into lunch within ½ an hour of coming round from her anaesthetic and was so happy to be rid of the tooth, that this was the only stationary photo I could take of her!

